

A Diagnosis of Tonsillitis using Image Processing and Neural Network

A. Leelasantitham and S. Kiattisin, Members

ABSTRACT

Tonsillitis is a disease occurring mostly in child and adults as this disease may take to the other effects. Nowadays, a detection of tonsil grand exploits medical doctor's diagnosis to check on oral cavity. Therefore, this paper presents a diagnosis of tonsillitis using image processing and neural network (NN). There are three steps described as follows. The first step is localization of tonsil grand (TG) using Ellipses Hough Transform. The second step is feature extraction using three important factors which can be indicated in swelling by images of TG in terms of a) a dimensional ratio of TG, b) an average intensity of TG and c) a purulent surface of TG (yes/no) using power spectrum of two dimensional Fast Fourier Transform (2D FFT). The final step is verification using NN. The three factors are inputted into NN, and TG samples of 50 images are used for training into the NN. They are divided by tonsillitis patience 25 images and usual TG of 25 images. This experiment uses 100 images of TG for testing NN. Therefore, the overall accuracy is at approximately 90% in terms of comparing with the results from the medical doctor.

Keywords: tonsillitis; diagnosis; neural network; image processing; 2D FFT, Ellipses Hough Transform

1. INTRODUCTION

Tonsil grand (TG) is the group of tissue type as lymphatic gland which is placed inside of buccal cavity called 'Palatine Tonsil'. The inflamed disease of tonsil is a swell of tonsil grand (like a little of tubercules) because of the mostly causes from infectiousness such as virus and bacteria. Tonsillitis is not a serious disease but the disadvantage of the inflamed TG will show its area in an oral cavity. If it has occurred both of inflammable and growing TG to a big grand, then a respiratory pathway of human will be clogged in their breath or else this infection may severely become a ulcer in throat. Infectious inci-

dence is occurred in the blood and it may affect, for example, the heated level of middle ear, the sinusitis, the bronchitis or the pneumonia. Such diseases are important problems in the tonsillitis of child in the case of the inflammation or the severe heart occurred from the infectious streptococcus. If it takes time to be chronic, then it may cause a valve disease with disabilities and heart failure [1].

Diagnosis of doctor will check the oral cavity to see any features of TG which is exposed for questioning symptoms of history from the patience. For diagnosis in oral cavity, the doctors will see directly the oral cavity to observe the features of TG, the disease can be intercommunication, and the patience has drawn a breath odor. An alternative method to help the medical doctor for diagnosis of the tonsil is the use of images and computer because the medical doctor will check the oral cavity to see closely the tonsil grand of the patience. As a result, he sometimes may receive the disease from the patience. To support the practical doctor, it has taken pictures in the oral cavity to see a feature of tonsil grand for instead of checking directly in the oral cavity. In open literature, only three related papers have involved with finding out the tonsil using images [2], [3]. Such two papers have checked two factors as follows: 1) a size of TG using the sized ratio of a usual TG (from the previous diagnosis) and a new TG (from the present diagnosis); as well as, 2) an average intensity of the area of TG. These two factors will be sent to fuzzy logic to make a decision. However the information of such two papers is not sufficient to analyze for checking tonsillitis because of only two factors (i.e. the size and intensity).

In this paper, a diagnosis of tonsillitis using image processing and neural network (NN). There are three steps described as follows. The first step is localization of tonsil grand (TG) using the Ellipses Hough Transform. The second step is feature extraction using three important factors which can be indicated in swelling by images of TG in terms of a) a dimensional ratio of TG, b) an average intensity of TG and c) a purulent surface of TG (yes/no) using power spectrum of two dimensional Fast Fourier Transform (2D FFT). The final step is verification using NN. The three factors are inputted into NN, and TG samples of 50 images are used for training into the NN. They are divided by tonsillitis patience 25 images and usual TG of 25 images. This experiment uses 100 images of TG for testing NN. Therefore, the overall accuracy

Manuscript received on September 30, 2009; revised on December 28, 2009

Adisorn Leelasantitham and Supaporn Kiattisin are from Computer and Multimedia Engineering, School of Engineering, University of the Thai Chamber of Commerce 126/1, Vibhavadee-Rangsit Road, Dindaeng, Bangkok 10400, Thailand

E-mail addresses: adisorn_lee@utcc.ac.th (A. Leelasantitham) supaporn_kai@utcc.ac.th (S. Kiattisin)

is at approximately 90% in terms of comparing with the results from the medical doctor.

2. FEATURES OF TONSIL GRANDS

Figure 1 shows tonsil grand (TG) called “Palatine Tonsil” to be two lymph nodes located in the oral cavity on the side of neck with nearly tongue base-ness where we can see it when we open a mount. Figure 2 shows the tonsillitis which the oral cavity can be found in the grown dimension and the timidly inflammable red. If it reaches severe inflammation, then it will be seen in translucent whites covering TG called as “ulcer” [4], [5].

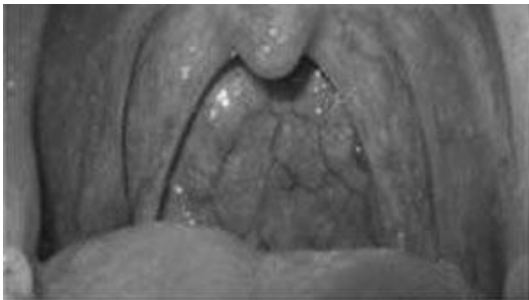

Fig.1: The usual tonsil grand [5].

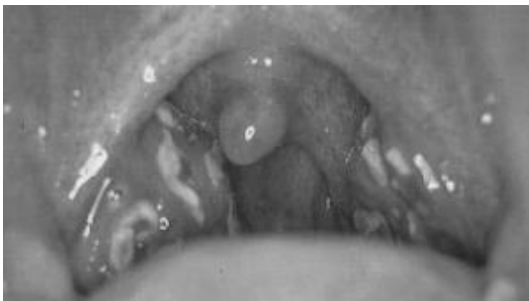

Fig.2: Tonsillitis called as “ulcer” [5].

3. PROPOSED METHODOLOGY

Figure 3 shows a system of the detection of tonsillitis images which the system consists of a tonsil grand (TG), a camera and a computer. The process is to start the camera capturing the TG and sending it to the computer for processing three factors i.e. 1) the dimensional ratio of TG, 2) the average intensity of TG and 3) the purulent surface of TG.

Figure 4 shows a flowchart of the detection of tonsillitis images based on medical knowledge and neural network. There are three main steps of the proposed methodology i.e. the localization, the feature extraction and the verification. The details of the three main steps can be described as follows.



Fig.3: A system of the detection of tonsillitis images.

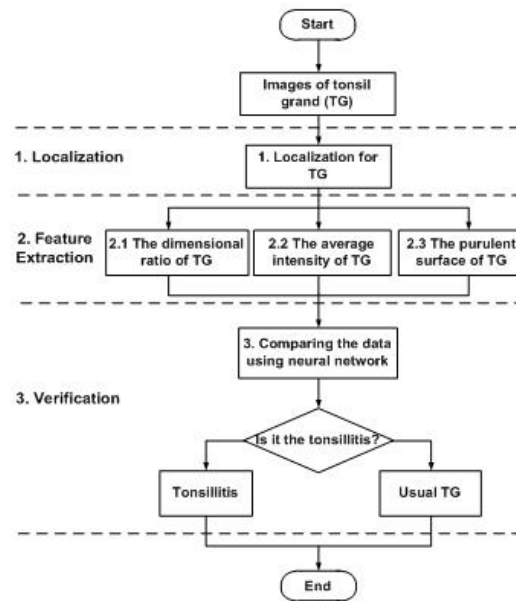


Fig.4: Flowchart for detection of tonsillitis images based on medical knowledge and neural network.

3.1 Localization

This paper uses the Ellipse Hough Transform (EHT) to find the edge of TG because the shape of TG is nearly related in ellipse shape. Therefore, the equation of the EHT can be defined as [6]

$$\frac{(u \cdot \cos \theta + v \cdot \sin \theta - x)^2}{a^2} + \frac{(-u \cdot \sin \theta + v \cdot \cos \theta - y)^2}{b^2} = 1 \quad (1)$$

where u and v are image point,

$H(x, y, a, b, \theta)$ is a hough space,

x, y, a, b and θ are parameters for the EHT.

Figure 5 shows an example for localizing the edge of TG. The process is started from a TG image converted to a binary image. As a result of the binary image of TG, the position of TG is located by the EHT. As shown in Figure 5, the dotted line of TG edge is generated by equation (1) until it finds out (0 or 1) all possible parameters (x, y, a, b, θ) that could pass (u, v) vote for parameters (x, y, a, b, θ) , then the solid line can cover the final edge of TG.

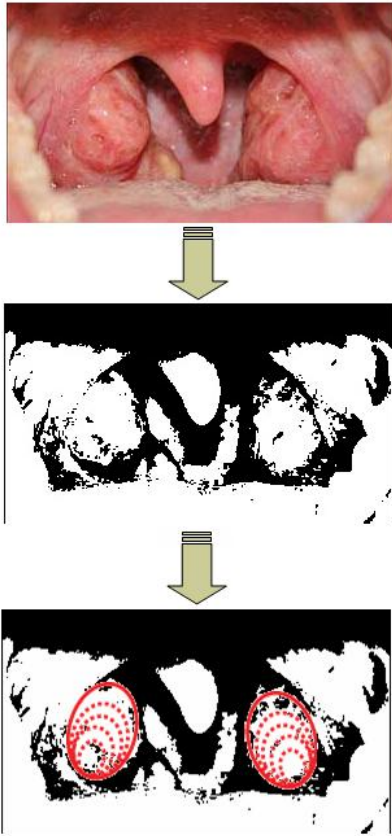


Fig.5: An example for localizing the edge of TG.

3.2 Feature Extraction

3.2.1 The dimensional ratio of TG

The first factor is a result of the TG dimensional ratio which can be found by measuring a size of TG (ellipse shape) which is the width (W) and height (H). The position of TG shape is obtained from the EHT. Therefore, the equation is equal to

$$R = \frac{W}{H} \quad (2)$$

which R is the dimensional ratio of width and height,

W is the width of TG (pixels),

H is the height of TG (pixels).

Figure 6 shows an example for finding the dimensional ratio of TG. The values (pixels) of W and H are obtained from the binary image which the shape of TG is related to the ellipse shape shown in Figure 6. Therefore, the result of the dimensional ratio of TG is calculated by equation (2). Note that the W and H are the minor and major axes, respectively, of ellipse shape.

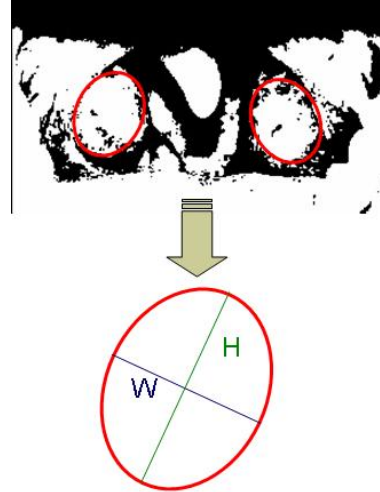


Fig.6: An example for finding the dimensional ratio of TG.

3.2.2 The average intensity of TG

The second factor is a result of the TG average intensity resulted from three colors (red, green and blue [R, G, B]) which are not the same values. R values are normally higher than G and B values in the TG image. However, there are some images which G or B values are nearly to R values. All R, G and B are important to use this method for verifying the TG image. For another reason, the TG generally is a high redness then it may be the tonsillitis, nevertheless it sometimes may not be the tonsillitis. Moreover, there are two factors i.e. the first and third factors being necessary to consider in this case. Such two factors will also be utilized for classification of the TG image (the normal TG and tonsillitis) using neural network (NN) which will be described further in Section 3.3.

In addition, there are usually many methods for classification of the normal TG and tonsillitis such as histogram intersection or Euclidean distance etc. However, there are limitations of such methods for classifying the TG image because they will classify only the data group in a linear model. In this work, the scattering plot is not clear for a separation of two data groups; however, some data also have overlapped between the normal and tonsillitis, as will be seen later in Section 3.3. As a result, it is difficult to classify both groups for a correction of the results. Therefore, this work proposes to use neural network for classification of the TG image i.e. the normal TG and tonsillitis.

The average intensity of TG exploiting the intensity of R, G and B in the TG area can be described as the formula

$$A = \frac{\sum_{i=1}^n r + \sum_{i=1}^n g + \sum_{i=1}^n b}{3n} \quad (3)$$

where A is the average intensity of TG area,
 r is the intensity of red,
 g is the intensity of green,
 b is the intensity of blue,
 n is the total pixels of the TG area.

Then, the average intensity (A) of TG area is normalized by 255 for a suitable value as following equation

$$N = \frac{A}{255} \tag{4}$$

where N is the normalized value of A (0 to 1).

Figure 7 shows an example for displaying the values of intensity (red, green and blue) on the area of TG. For example, it can be seen from Figure 7 that the values of a pixel (in case of $n = 1$) selected from the TG area consist of $r = 198$, $g = 118$ and $b = 69$. Therefore, the average intensity (A) using equation (3) is equal to $(198+118+69)/3 = 128.33$. In case of $n 1$, the average intensity (A) is calculated from the TG area for $n 1$ and, the summations of r , g , and b are obtained from $n 1$. Finally, the average intensity (A) will be normalized by 255 for the suitable value, as shown in equation (4).

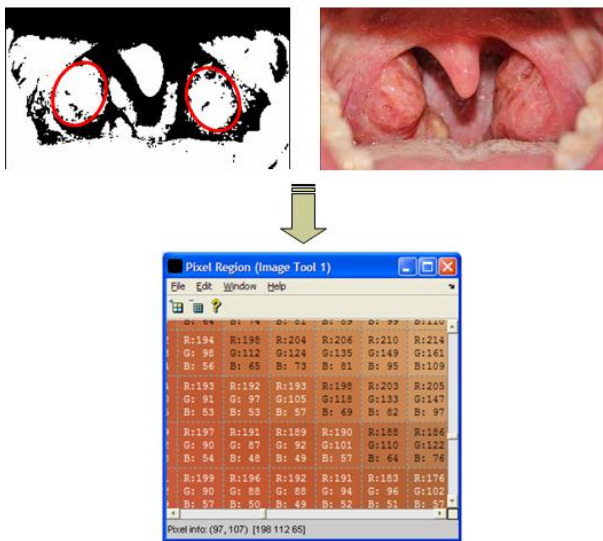


Fig.7: An example for displaying the values of intensity (red, green and blue) on the area of TG.

3.2.3 The purulent surface on TG

The third factor is to calculate a result of a surface on TG using the power spectrum of 2 dimensional Fast Fourier Transform (2D FFT). For example, if the calculated result reveals smooth surface on the TG, then it may be a normal TG whilst if the calculated result shows purulent surface on the TG, then it may

be an inflammation of the TG. Therefore, the 2D FFT and power spectrum of 2D for calculating the result of the surface on the TG will be defined as follows [7]

$$F(u, v) = \frac{1}{MN} \sum_{x=0}^{M-1} \sum_{y=0}^{N-1} f(x, y) e^{-j2\pi(ux/M+vy/N)} \tag{5}$$

where $F(u, v)$ is the 2D FFT result of picture,
 N, M are width and height of picture,
 $f(x, y)$ is brightness value at (x, y) .

The result from the equation (5) is taken to calculate the power spectrum of 2D as the equation

$$P(u, v) = |F(u, v)|^2 = R^2(u, v) + I^2(u, v) \tag{6}$$

where P is the power spectrum of 2D,
 R is real part,
 I is imaginary part.

Figure 8 shows an example of the resulting image using the 2D FFT on the area of TG. It can be seen from Figure 8 that the binary image of the TG area is applied for equation (5). Therefore, the 2D FFT image of the TG area is shown in Figure 8. Figure 9 shows a resulted graph derived from Figure 8 around the TG area using the 2D FFT. It can be seen from Figure 9 that the calculated value of power spectrum of 2D FFT image is at approximately 9.05×10^4 i.e. it will be the purulent surface on the TG (or tonsillitis). Note that the power spectrum (P) of 2D FFT is derived from the resulting values in equation (5) substituted in equation (6).

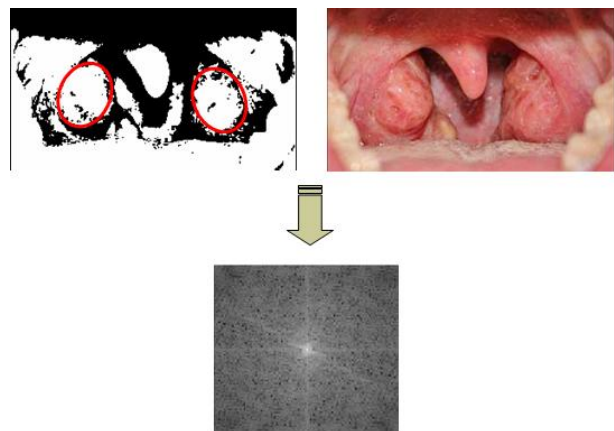


Fig.8: An example of the resulting image using the 2D FFT on the area of TG.

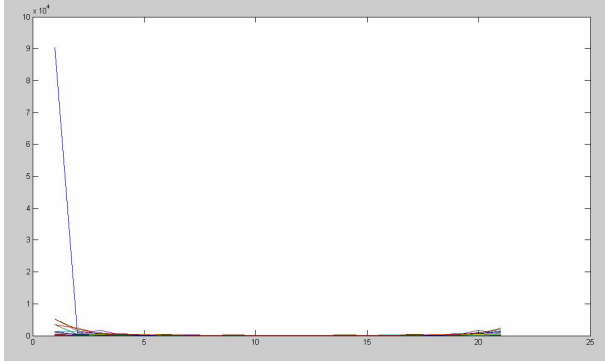


Fig.9: An example of a graph for the power spectrum of the 2D FFT image around the TG area.

3.3 Verification

3.3.1 Data Analysing

This section describes an analysis of the data consisting of three important factors based on medical knowledge. Such three important factors are as follows:

- the dimensional ratio of TG,
- the average intensity of TG and
- the purulent surface of TG.

The values of these three factors are plotted on three axes consisting of the width/height (W/H), the average intensity and the purulent surface for the first, second and third axes, respectively. The plotted values of the W/H, the average intensity and the purulent surface are derived from the equations (2), (4) and (6), respectively. Therefore, the scattering plot of the three important factors will be shown in Figure 10. As shown in Figure 10, symbols of ‘●’ and ‘×’ are represented to the usual TG and tonsillitis, respectively. It can be seen from Figure 10 that the data groups of ‘●’ and ‘×’ cannot be classified clearly in terms of a simple method of linear analysis because there is some data overlapped between two groups. Therefore, neural network is an alternative method for solving this classification which will be described further in Section 3.3.2.

3.3.2 Neural Network

This section designs neural network (NN) using a WEKA package [8] which there are 3 layers i.e. input, hidden and output layers, as shown in Figure 11. Numbers of nodes consist of 3, 2 and 2 nodes for the input, hidden and output layers, respectively. It can be seen from Figure 11 that the three factors (the W/H, the average intensity and the purulent surface) are inputted to the input layer whilst there are 2 nodes for the output layer consisting of the usual TG (value = 0) and tonsillitis (value = 1). The equation for calculation of backpropagation neural network can be defined as [9]

$$\Delta W_{ij} = \eta \delta_i x_j + \alpha \Delta W_{ij}(k-1) \quad (7)$$

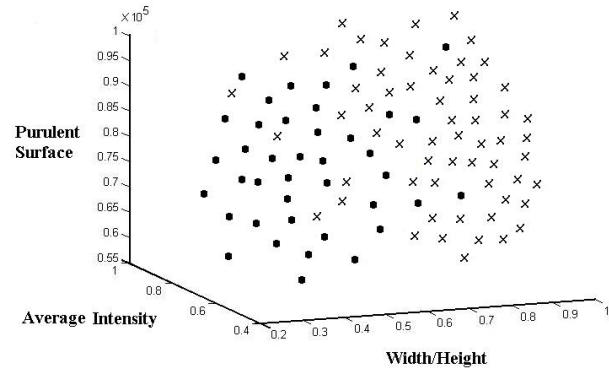


Fig.10: The scattering plot of the three important factors.

which W_{ij} is weight to connect between output node j and input node i

η is step size

α is coefficient of momentum

x_j is input signal from node j

δ_i is the quantity of difference of error, δ_i can be shown as below

for output unit

$$\delta_i = \{O'_i(t_i - O_i)\}$$

otherwise

$$O'_i \sum W_{mi} \delta_m \quad (8)$$

O'_i is derivative of O_i

T_i is a required signal to node i

O_i the actual output at node i .

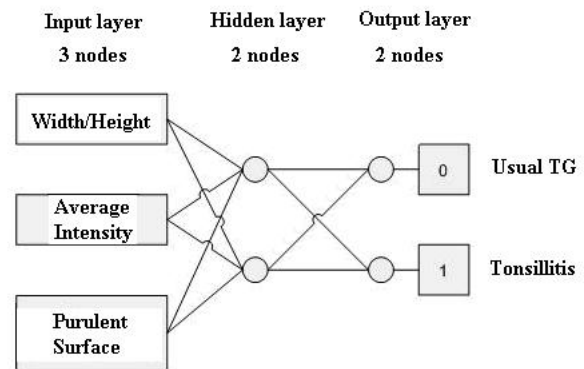


Fig.11: Designing three layers of neural network.

4. EXPERIMENTAL RESULTS AND DISCUSSIONS

This section will verify the proposed method for the detection of tonsillitis images based on medical

knowledge and neural network (NN). This paper uses a MATLAB program for implementation of the first part of image processing and the second part of NN using a WEKA package [8]. Details of preparing the neural network can be described as follows:

a) To demonstrate data inputs for training of neural network, there are 25 images of tonsillitis whilst there are 25 images of the usual TG.

b) To demonstrate data inputs for testing the detection of tonsillitis, there are 100 images of TG. They are taken into NN.

Table 1 shows the testing results of verifying TG images which the output results are the usual TG or tonsillitis. It can be seen in Table 1 that the 100 images of TG are tested by both of the medical doctor and the proposed method. As shown in Table I, the results from the medical doctor can diagnosis the following outputs i.e. 40 and 60 images for the usual TG and tonsillitis, respectively; whilst the results from the proposed method can classify the following outputs i.e. 35 and 55 images for usual TG and tonsillitis, respectively. There is an error image of them for the usual TG which their accuracy is at approximately 87.5%, whilst; there is also an error image of them for the tonsillitis which their accuracy is at approximately 91.67%. Therefore, the overall accuracy is at approximately 90%.

Table 2 shows summary results of the true or false positive, and the true or false negative. It can be seen in Table 2 that there are 35 images for the true positive being the usual TG whilst there are five images for the false positive being the tonsillitis. As shown in Table 2, there are 55 images for the true negative being the tonsillitis whilst there are five images for the false negative being the usual TG. From the experimental results, the correct results depend on clear images, and NN is considered in terms of numbers of training set. If there are more samples of training set, the new results will chance an increment from the old results.

Table 1: The testing results of verifying TG images.

Output Results of TG Images	Correct Results From Medical Doctor	Correct Results From The Proposed Method	Accuracy (%)
Usual TG	40	35	87.5
Tonsillitis	60	55	91.67

Table 2: Summary results of the true or false positive, and the true or false negative.

	True	False
Positive	35	5
Negative	55	5

5. CONCLUSION

This paper has presented the diagnosis of tonsillitis using image processing and neural network (NN). There are three steps described as follows. The first step is localization of tonsil grand (TG) using the Ellipses Hough Transform. The second step is feature extraction using three important factors which can be indicated in swelling by images of TG in terms of a) a dimensional ratio of TG, b) an average intensity of TG and c) a purulent surface of TG (yes/no) using the power spectrum of two dimensional Fast Fourier Transform (2D FFT). The final step is verification using NN. The three factors are inputted into NN, and TG samples of 50 images are used for training into the NN. They are divided by tonsillitis patience 25 images and usual TG of 25 images. This experiment uses 100 images of TG for testing NN. Therefore, the overall accuracy is at approximately 90% in terms of comparing with the results from the medical doctor.

6. ACKNOWLEDGMENT

The authors are grateful to Mr. Kritchanon Jirawanitcharoen for his useful help in this work.

References

- [1] Medical Doctor Worawut Chareonsiri: <http://www.bangkokhealth.com>
- [2] P. Phensadsaeng, P. Kumhom, and K. Chamnongthai, 2005, "A Method of Vision-Based Tonsillitis Detection", *Sixth International Conference on Intelligent Technologies (InTech'05)*, 14-16 December 2005, Phuket, pp. 789-792.
- [3] P. Phensadsaeng, P. Kumhom, and K. Chamnongthai, 2006, "A Computer-aided-Diagnosis of Tonsillitis Using Tonsil size and color", *International Symposium on Circuits and System (ISCAS2006)*, Greece, May 21-24, 2006, pp. 5563-5566.
- [4] Medical Doctor Panuwit Pumhirun: <http://www.vichaiyut.co.th>
- [5] K. Jirawanitcharoen, S. Kiattisin, A. Leelasantitham and P. Chairapa, "A Method of Detecting Tonsillitis Images Based on Medical Knowledge and Neural Network", *The 2009 International Conference on Artificial Intelligence and Neural Networks (ICAINN 2009)*, Beijing, China, August 8-11, 2009.
- [6] X. Yu, H.W. Leong, C. Xu and Q. Tian, "A robust and accumulator-free ellipse hough transform", *Proceedings of the 12th ACM International Conference on Multimedia (ACM Multimedia 2004)*, New York, USA, October 10-16, 2004, pp. 256-259.
- [7] C. Gonzalez, Rafael and E. Woods, Ricard, *Digital Image Processing 2nd*, Prentice Hall, 2002.
- [8] I. H. Witten and E. Frank, *Data mining: Practi-*

cal machine learning tools and techniques (2 ed.), Morgan Kaufmann, San Francisco, CA, 2005.

- [9] Dan W. Patterson, *Artificial Neural Networks Theory and Application*, Prentice Hall, 1996.



Adisorn Leelasantitham received the B.Eng. degree in Electronics and Telecommunications and the M.Eng. degree in Electrical Engineering from King Mongkut's University of Technology Thonburi (KMUTT), Thailand, in 1997 and 1999, respectively. He received his Ph.D. degree in Electrical Engineering from Sirindhorn International Institute of Technology (SIIT), Thammasat University, Thailand, in 2005. He is currently the Assistant Professor in Department of Computer and Multimedia Engineering, School of Engineering, UTCC, Thailand. His research interests include analog circuits, image processing, medical images, computer graphics, AI, neural networks, embedded systems and robotics.



Supaporn Kiattisin received B.Eng. in Computer Engineering from Chiangmai University in 1995, M.Eng. in Electrical Engineering and Ph.D. in Electrical and Computer Engineering from King Mongkuts University of Technology Thonburi (KMUTT), Bangkok, Thailand. She currently works at Computer Engineering and Multimedia, School of Engineering, University of the Thai Chamber of Commerce (UTCC).

Her research interests include medical imaging, computer vision and modeling. She is member of TESA, ThaiBME, IEICE and IEEE .